

Axial/Appendicular

Divisions of the Human Skeleton

Axial Skeleton

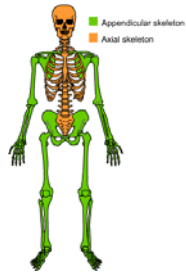vertebral column
skull
thorax

Appendicular Skeleton

upper limb bones
lower limb bones

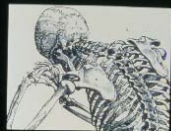Appendicular Skeleton

- Upper Limb (Arm) bones
- Pectoral Girdle
- Lower Limb (leg bones)
- Pelvic girdle



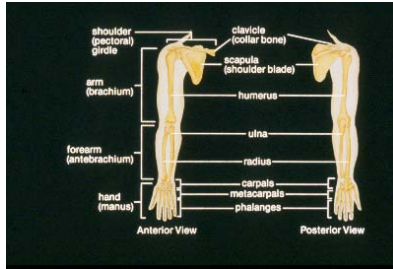
Upper Limb

Anatomy of the Upper Limbs

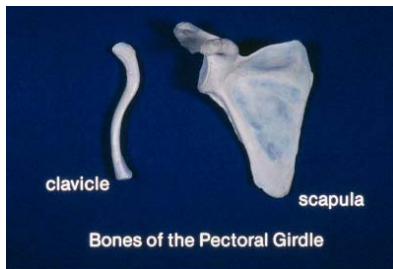

© 1992 by BIOLOGY MEDIA, Berkeley, CA
All Rights Reserved.

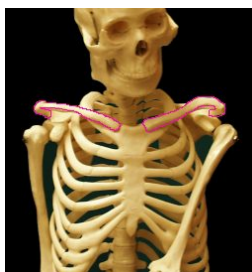Upper Limb Bones



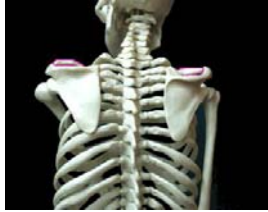Pectoral (Shoulder) Girdle



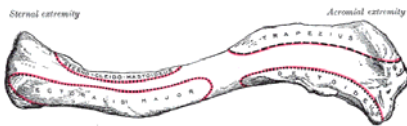
Clavicle (2)



Clavicle (Posterior)

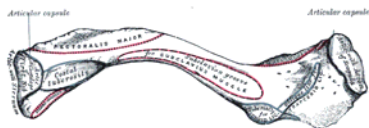


Clavicle (Superior View)



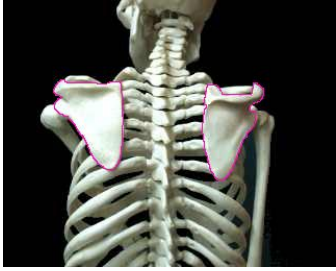- Sternal (medial) end
- Lateral end (for acromion)

Clavicle (Inferior)



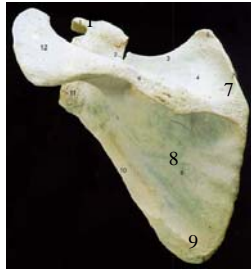
- Costal tuberosity (costoclavicular ligament)
- Trapezoid line
- Conoid tubercle

Scapula (Posterior)



Scapula (Posterior)

- 1. Coracoid Process
- 2. Scapular Notch
- 3. Superior Margin
- 4. Supraspinatus Fossa
- 5. Superior Angle
- 6. Scapular Spine
- 7. Vertebral Margin
- 8. Infraspinatus Fossa
- 9. Inferior Angle
- 10. Lateral (Axillary) Margin
- 11. Glenoid Cavity
- 12. Acromion (Process)



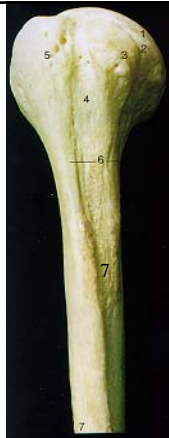
Scapula (Lateral)



- 1. Coracoid Process
- 2. Glenoid Cavity
- 3. Scapular Spine
- 4. Acromion Process
- 5. Infraspinatus Fossa
- 6. Inferior Angle
- 7. Axillary Margin

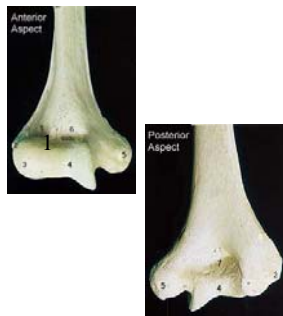
Humerus (Proximal)

- 1. Head
- 2. Anatomical Neck
- 3. Lesser Tubercle
- 4. Intertubercular (bicipital) Groove
- 5. Greater Tubercle
- 6. Surgical Neck
- 7. Deltoid Tuberosity



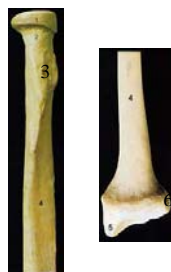Distal Humerus

- 1. Radial Fossa
- 2. Lateral Epicondyle
- 3. Capitulum
- 4. Trochlea
- 5. Medial Epicondyle
- 6. Coronoid Fossa
- 7. Olecranon Fossa



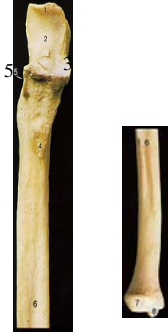Radius

- 1. Head of Radius
- 2. Neck of Radius
- 3. Radial Tuberosity
- 4. Radius (Shaft)
- 5. Styloid Process
- 6. Ulnar Notch
- Intersosseous crest



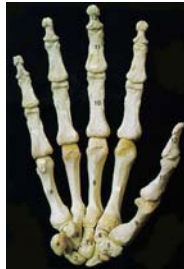Ulna

- 1. Olecranon Process
- 2. Trochlear (semilunar) Notch
- 3. Coronoid Process
- 4. Tuberosity
- 5. Radial Notch
- 6. Ulna (Shaft)
- 7. Head of Ulna
- 8. Styloid Process
- Interosseous crest



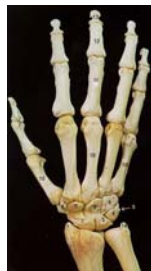Hand

- **Carpals**
- **Metacarpals**
- **Hand Phalanges**



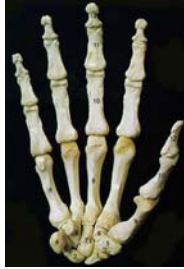Hand (Dorsal)

- 1. Styloid Process of Radius
- 2. Navicular (Scaphoid)
- 3. Lunate
- 4. Triquetral
- 5. Pisiform
- 6. Trapezium
- 7. Trapezoid
- 8. Capitate
- 9. Hamate
- 10. Metacarpal
- 11. Proximal Phalange
- 12. Middle Phalange
- 13. Distal Phalange
- 14. Styloid Process of Ulna



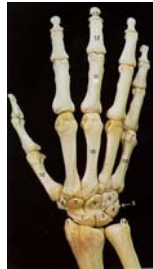Hand (Palm)

- 1. Navicular (Scaphoid)
- 2. Lunate
- 3. Triquetral
- 4. Pisiform
- 5. Trapezium
- 6. Trapezoid
- 7. Capitate
- 8. Hamate
- 9. Metacarpal
- 10. Proximal Phalange
- 11. Middle Phalange
- 12. Distal Phalange

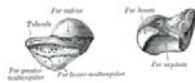

Proximal Row Carpals

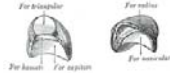- Scaphoid-#2
- Lunate-#3
- Triquetrum-#4
- Pisiform-#5



Scaphoid (=like a boat)



Lunate (luna=moon)



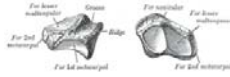Triquetrum (triquetrus = 3-
cornered shape)



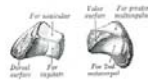
Pisiform (pisum=pea)



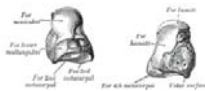
Trapezium (geometrical figure having 2 parallel and two diverging sides)



Trapezoid (high cut boot)



Capitate (caput= head)



Hamate (=hook)



Distal Row Carpals

- Trapezium #5
- Trapezoid #6
- Capitate #7
- Hamate #8